



Modified tubeless minimally invasive percutaneous nephrolithotomy for management of renal stones in children: A single-centre experience

Ahmed Sebaey, Ashraf Abdelaal, Alaa Elshaer, Hisham Alazaby, Wael Kadeel, Tarek Soliman & Ehab Elbarky

To cite this article: Ahmed Sebaey, Ashraf Abdelaal, Alaa Elshaer, Hisham Alazaby, Wael Kadeel, Tarek Soliman & Ehab Elbarky (2019) Modified tubeless minimally invasive percutaneous nephrolithotomy for management of renal stones in children: A single-centre experience, Arab Journal of Urology, 17:4, 285-291, DOI: [10.1080/2090598X.2019.1659473](https://doi.org/10.1080/2090598X.2019.1659473)

To link to this article: <https://doi.org/10.1080/2090598X.2019.1659473>



© 2019 The Author(s). Published by Informa UK Limited, trading as Taylor & Francis Group.



Published online: 04 Sep 2019.



[Submit your article to this journal](#)



Article views: 58



[View related articles](#)



[View Crossmark data](#)

Modified tubeless minimally invasive percutaneous nephrolithotomy for management of renal stones in children: A single-centre experience

Ahmed Sebaey, Ashraf Abdelaal, Alaa Elshaer, Hisham Alazaby, Wael Kadeel, Tarek Soliman and Ehab Elbarky

Department of Urology, Benha Faculty of Medicine, Benha University, Benha, Egypt

ABSTRACT

Objectives: To evaluate the safety, effectiveness and morbidity, as well as the usefulness of a modified supine mini-percutaneous nephrolithotomy (PCNL) for managing renal stones in children.

Patients and methods: We studied 50 children, from September 2017 to September 2018, who were aged 4–16 years with a single renal pelvic or calyceal stone of <2 cm. We used a 9-F short ureteroscope through a 16-F metal access sheath with an alternative approach that allows a second percutaneous procedure using the same tract. If a residual stone was present, we recovered the track back through the exteriorised ureteric catheter at the flank.

Results: Of all 50 patients, 48 (96%) underwent the modified supine mini-PCNL technique, which produced a primary stone-free rate of 80% that increased to 100% after treating the residual stones by a second look. The mean operative and fluoroscopic times were 89.10 and 7.68 min, respectively. One case (2%) had significant bleeding and one case (2%) had pelvic perforation; and a nephrostomy tube was inserted in both cases. The mean haemoglobin drop was 0.91 g/dL ($P < 0.001$). The mean hospital stay was 1.42 days and the mean pain score was 2.08, the pain score was 5 in the two cases in which a nephrostomy tube was inserted.

Conclusion: The modified supine mini-PCNL is a safe and effective method for managing renal stones in children, with less postoperative pain and discomfort, less analgesic requirement, and provides access back for a second look.

Abbreviations: ESWL: extracorporeal shockwave lithotripsy; Hb: haemoglobin; PCNL: percutaneous nephrolithotomy; SFR: stone-free rate

ARTICLE HISTORY

Received 2 July 2019
Accepted 3 August 2019

KEYWORDS

Tubeless mini-percutaneous nephrolithotomy; renal stones; children; second-look access

Introduction

Renal stone disease in children is uncommon. However, it represents a clinical management dilemma due to the size of the urinary tract and the risk of recurrence. The majority of renal stones are due to metabolic disorders or infection with a high risk of recurrence [1]. In the past, open surgery was the only treatment modality available to children, and multiple open operations with their related morbidities were not an uncommon occurrence [2].

According to the updated European Association of Urology (EAU) guidelines, percutaneous nephrolithotomy (PCNL) is recommended as the therapy of choice for large renal calculi (>2.0 cm) and also for smaller stones (1.0–2.0 cm) of the lower renal pole when unfavourable factors for extracorporeal shockwave lithotripsy (ESWL) exist [3]. Excellent stone-free rates (SFRs) after PCNL have been reported, ranging from 76% to 98% [4].

Recently, minimally invasive PCNL or mini-PCNL was developed to decrease morbidity associated with larger instruments such as blood loss, postoperative pain, and potential renal damage. Mini-PCNL is performed with a miniature endoscope via a small percutaneous tract

(11–20 F). Mini-PCNL was described as an alternative percutaneous approach to large renal stones in the paediatric patient population. Furthermore, it has become a treatment option for adults as well, and it is used as a treatment for calculi of various sizes and locations [5].

The placement of a nephrostomy catheter at the end of the PCNL has been considered the standard procedure, which is thought to act as a tamponade to stop bleeding, provide adequate renal drainage, and make an additional nephroscopy easier [2]. However, nephrostomy catheters have been associated with prolonged hospitalisation, urine extravasation, and significant postoperative pain and discomfort [6].

In recent years, there has been an increase in the number of percutaneous surgeries that, once the procedure has been completed, dispense with the use of nephrostomy, leaving internal drainage through a JJ or ureteric catheter. This modality, known as ‘tubeless’, has been shown to cause less postoperative pain, reduce analgesia requirements, and shorten hospital stays [7]. The major disadvantage of tubeless PCNL is losing the option to perform an early second-look nephroscopy in cases of residual stones, considering that up to 16% of

tubeless PCNL require some type of auxiliary procedure to render the patient stone-free [8].

Placement of an external 5-F ureteric stent below the renal pelvis after the mini-PCNL without a JJ stent, modified tubeless mini-PCNL would provide adequate drainage of the kidney and minimise postoperative discomfort without complications and the possibility of a second-look nephroscopy [6].

In the present study, we report our experience of a modified supine mini-PCNL in the management of renal stones in children using a 9-F short ureteroscope through a 16-F metal access sheath with an alternative approach that allows a second percutaneous procedure using the same tract.

Patients and methods

Between September 2017 and September 2018 50 patients, aged 4–16 years, admitted to the Urology Department presenting with a single renal pelvis or calyceal stone (1–2 cm) were treated using the modified tubeless mini-PCNL technique. The diagnosis was achieved by pelvic abdominal ultrasonography, plain X-ray and CT in all patients. Exclusion criteria were: untreated UTIs; uncorrectable coagulopathy; congenital anomalies in the kidney, such as ectopic pelvic kidney or horseshoe kidney; unfavourable anatomy; and multiple or Staghorn stones. Informed consent was obtained from the parents of all patients. Preoperative laboratory investigations included complete blood count, coagulation profile, liver and renal function tests, urine analysis, urine culture in cases of UTI, and fasting blood sugar. Prophylactic antibiotics were administered routinely. General anaesthesia was used in all patients according to the standard technique.

Post-procedural radiological screening (ultrasonography and radiography) was done to evaluate the extent of stone clearance within 2 weeks of surgery. Postoperative stone-free status was defined as no visible stones on imaging or residual fragments of <0.4 cm.

Patients' demographic data, stone characteristics, procedural information (operative time, fluoroscopic time, intraoperative morbidity, PCNL puncture access time and access trials, patient position, and blood transfusion), post-treatment outcomes (postoperative haemoglobin [Hb], mean Hb drop, SFR, hospital stay, and analgesic requirement) were prospectively documented.

Operative technique

The patient was placed in lithotomy and a 5-F retrograde end-flushing ureteric catheter was inserted. The tip of the catheter was sited at the renal pelvis or within the upper pole calyx, and its position was confirmed by instilling a small amount of radiographic contrast medium into the collecting system. A Foley catheter, (6–10 F) depending

on the patients' age and urethral calibre, was inserted per urethra and taped to the ureteric catheter.

In all 50 patients, we performed the manoeuvre in a supine position with the side of interest at the edge of the table with a small cushion placed under the flank to elevate it 15–20°, followed by sterilisation of the skin with povidone-iodine 10% solution and draping of the patient. The patient was kept warm throughout the procedure because of the increased risk of hypothermia in the paediatric population.

The renal collecting system was opacified by retrograde injection of contrast medium via the end-flushing catheter, and a mobile fluoroscopy C-arm was used to identify the calyx to be punctured. The selected calyx was punctured under fluoroscopic guidance. Once the calyx was accessed, an angled-tip, 0.089 cm (0.035 inch) diameter, 180 cm length, hydrophilic guidewire was negotiated past the stone into the distal ureter and preferably into the bladder.

The track was then dilated sequentially using plastic fascial dilators of 6, 8, and 10 F up to 16 F (Figure 1). The 16-F metal sheath was then passed over the 16-F dilator (Figure 2), and once the tip of the sheath was confirmed to be within the collecting system, the dilator was removed under fluoroscopic guidance (Figure 3). Stones were fragmented using a semi-rigid 9-F short ureteroscope and pneumatic lithoclast, and the fragments removed sequentially by using various types of stone grasping (Figure 4).

For those cases in which the decision was made to perform the modified supine mini-PCNL, the ureteric catheter was exteriorised through the 16-F sheath using ureteroscope forceps (Figure 5)

In the cases where a single J was antegradely inserted, a straight 0.089 cm (0.035 inch) diameter guidewire was retrogradely inserted through the ureter then this wire was exteriorised through the 16-F sheath and with the use of ureteroscope forceps a single J was inserted over this wire under fluoroscopic guidance (Figure 6).

The incision of the nephrostomy tracts was closed with silk sutures. In cases in which the patient was categorised as stone free, the ureteric catheter was withdrawn along with the Foley catheter. In the presence of residual stones and the need for a second-look, the patient was taken to the operating room, placed under general anaesthesia and a flexible guidewire was inserted through the catheter lumen, recovering the trajectory.

Results

This study included 50 patients (32 boys and 18 girls) with a solitary renal pelvis or calyceal stone (right side in 20 patients and left side in 30). The mean (SD; range) age of the patients was 8.64 (3.19; 4–16) years. Four patients (8%) had a history of ipsilateral pyelolithotomy, while three patients (6%) had had ipsilateral ESWL. The mean (SD; range) stone size, operative and fluoroscopy times were

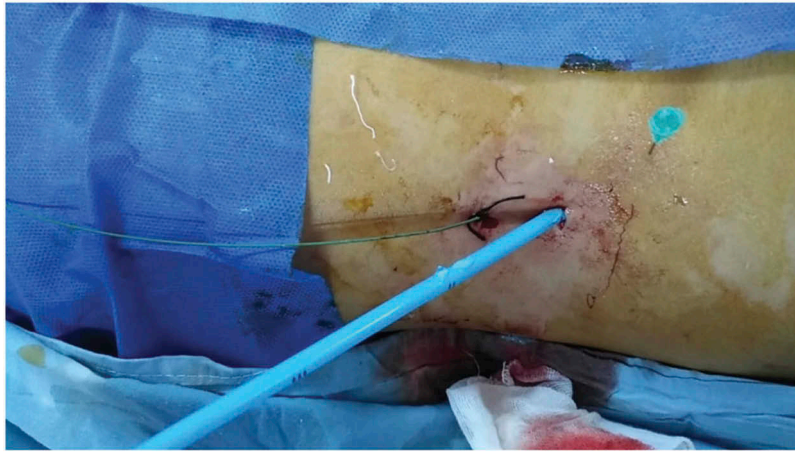


Figure 1. The 16-F dilator.

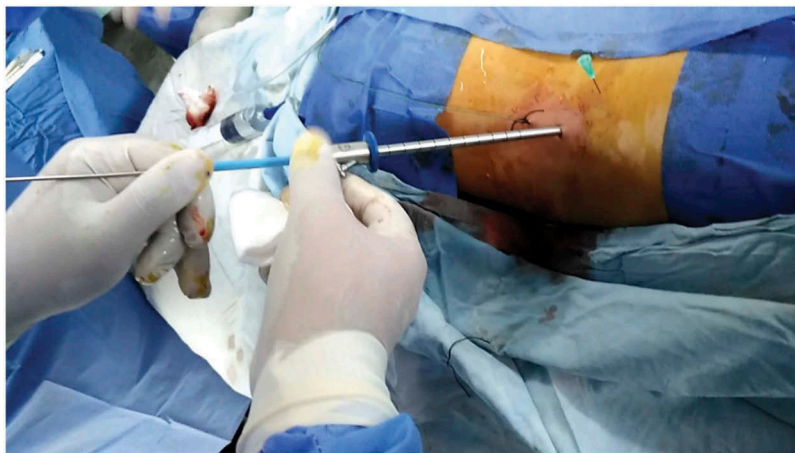

Figure 2. Inserting the 16-F metal sheath over the 16-F dilator.

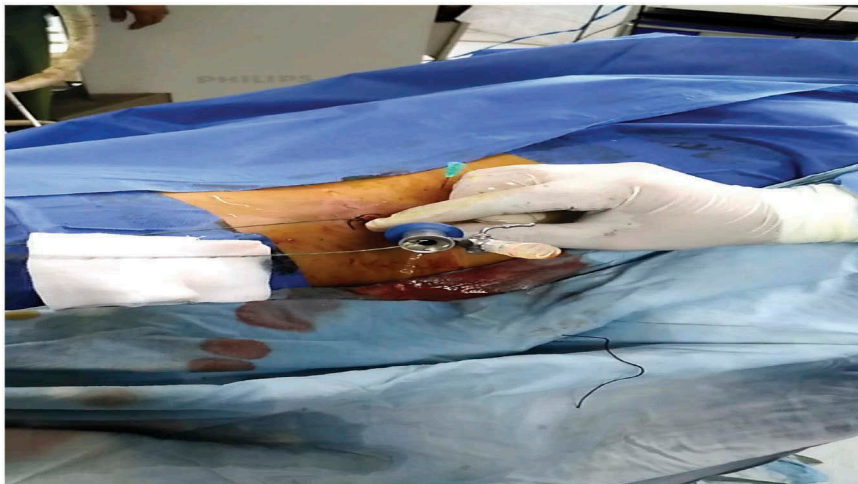


Figure 3. The 16-F sheath after removal of dilators.

1.52 (0.29; 1–2) cm, 89.10 (29.39; 40–120) min, 7.68 (2.21; 3–10) min, respectively. In all, 40 patients (80%) had radiopaque stones and 10 (20%) had radiolucent stones (Table 1). The mean (SD; range) hospital stay was 1.42 (0.53; 1–3) days. The mean (SD) preoperative Hb level was 12.79 (1.0) g/dL and postoperatively was 11.88 (1.08) g/dL;

and the mean (SD; range) Hb drop was 0.91 (0.47; 0.5–2.0) g/dL ($P < 0.001$) (Table 2). Although this difference was statistically significant, it had minimal clinical repercussions, as only one case (2%) had significant bleeding for which 1 unit blood was transfused. One patient (2%) had renal pelvic perforation and extravasation, this was a small



Figure 4. Stones after disintegration.

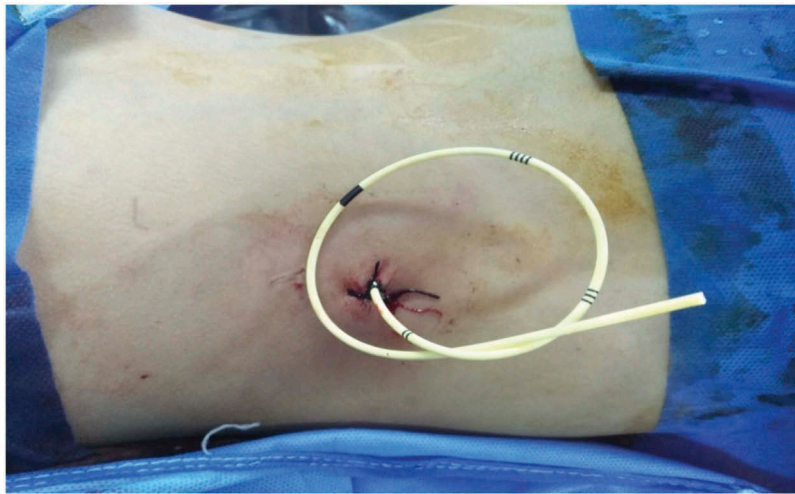

Figure 5. Externalised ureteric catheter at the flank.

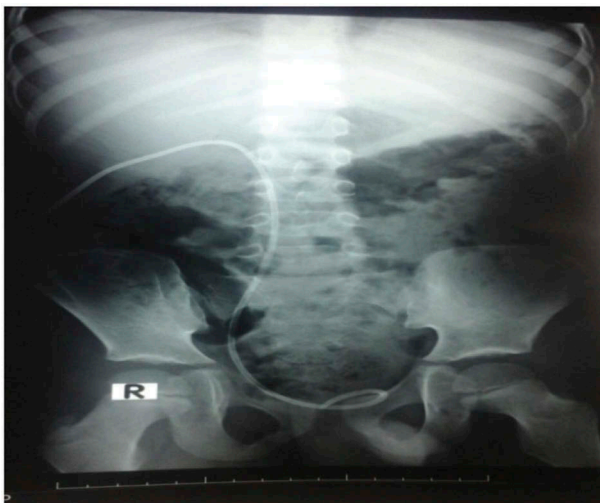

Figure 6. KUB of externalised single J at the flank.

perforation and resolved with JJ stenting and conservative measures; and a nephrostomy tube was inserted in both cases. Two cases (4%) developed a postoperative fever.

Externalisation of the ureteric catheter through the flank was performed in 48 cases (96%). The primary

SFR was 80% that increased to 100% after successfully treating the residual fragments by a second procedure through the externalised ureteric catheter.

The mean (SD; range) pain score was 2.08 (1.05; 1–5), the pain score was 5 in the two cases in which a nephrostomy tube was inserted. The mean (SD) post-operative analgesia was 89.8 (8.52) mg in which we used diclofenac sodium injection (Table 2). Procedure complications are listed according to the modified Clavien–Dindo score [9] in Table 3.

Discussion

Open surgery as a treatment modality for renal stones in children is now rarely performed. PCNL has been identified globally as a safe procedure associated with an appreciable greater success rate along with lesser major associated surgical complications, thus replacing open surgeries in many cases [10]. Recently, several reports have suggested that the risk of bleeding is associated with sheath size. Thus, to decrease morbidity related to larger tracts, such as bleeding, postoperative pain, and potential renal damage, modifications to the

Table 1. Demographic and stone characteristics of the 50 children.

Variable	Value
Age, years, mean (SD; range)	8.64 (3.19; 4.0–16.0)
Sex, n (%)	
Male	32 (64.0)
Female	18 (36.0)
BMI, kg/m ²	
Mean (SD; range)	20.98 (2.82; 17.0–29.0)
17–<24, n (%)	45 (90.0)
≥24, n (%)	5 (10.0)
Past surgical history, n (%)	
Left ESWL	2 (4.0)
Left stone kidney Open	3 (6.0)
Right ESWL	1 (2.0)
Right stone kidney Open	1 (2.0)
–ve	43 (86.0)
Stone size, cm, mean (SD; range)	1.52 (0.29; 1.0–2.0)
Stone site, n (%)	
Lower calyx	19 (38.0)
Lower calyx + pelvis	2 (4.0)
Pelvis	19 (38.0)
Upper calyx	5 (10.0)
Middle calyx	5 (10.0)
Stone side, n (%)	
Right	20 (40.0)
Left	30 (60.0)
Stone opacity, n (%)	
Opaque	40 (80.0)
Lucent	10 (20.0)

Table 2. Perioperative data.

Variable	Value
Preoperative Hb, g/dL, mean (SD; range)	12.79 (1.0; 11.5–14.5)
Preoperative UTI, n (%)	
+ve	3 (6.0)
–ve	47 (94.0)
Operative time, min, mean (SD; range)	89.10 (29.39; 40–120)
Fluoroscopic time, min, mean (SD; range)	7.68 (2.21; 3.0–10.0)
Blood transfusion, n (%)	
Yes	1 (2.0)
No	49 (98.0)
Intraoperative morbidity, n (%)	
Bleeding	1 (2.0)
Perforation	1 (2.0)
–ve	48 (96.0)
Modified tubeless or not, n (%)	
Modified tubeless	48 (96.0)
With tube	2 (4.0)
Access time, min, mean (SD; range)	1.32 (0.83; 0.25–3.0)
Access trials, n, mean (SD; range)	2.58 (1.37; 1–5)
Postoperative morbidity, n (%)	
Fever	2 (4.0)
–ve	48 (96.0)
Postoperative Hb, g/dL, mean (SD; range)	11.88 (1.08; 9.5–14.0)
SFR, n (%)	
Residual (second look)	10 (20.0)
Stone-free	40 (80.0)
Hospital stay, days, mean (SD; range)	1.42 (0.53; 1–3)
Pain score, mean (SD; range)	2.08 (1.05; 1–5)
Postoperative analgesia, mg, mean (SD; range)	89.8 (8.52; 60–125)
Hb drop, g/dL, mean (SD; range)	0.91 (0.47; 0.50–2.0)

technique and size of the instruments have been made. The mini-PCNL was originally developed for the management of renal stones in paediatric patients [11]. Mini-PCNL shares a comparable clearance rate as standard PCNL, but is associated with a lesser Hb drop, hospital stay, analgesic requirements, and complications [12]. When mini-PCNL performed in children and adults were compared, there was no significant difference in

Table 3. Complications according to modified Clavien–Dindo System.

Grade	Complication	N (%)
I	Fever	2 (4)
II	Blood transfusion	1 (2)
IIIa	Urinoma (treated conservatively)	1 (2)
IIIb	Need an intervention under GA	0
IVa	Organ injury or dysfunction	0
IVb	Multiple organ injury or dysfunction	0
V	Death	0

GA, general anaesthesia.

the perioperative total complication rate, and major complications (Clavien–Dindo Grade IV and V) were not observed in children [13]. Compared with ESWL, mini-PCNL has been reported to have significantly higher SFRs, especially for renal stones >1 cm [14]. While, compared to retrograde intrarenal surgery, mini-PCNL has shown better SFRs for the management of larger renal stones (2–3 cm) and large impacted upper ureteric stones, but similar effectiveness was reported when treating smaller renal stones between both procedures [15]. In the standard technique of PCNL, a nephrostomy tube is placed at the end of the procedure to act as a tamponade to stop bleeding, provide adequate renal drainage, and makes an additional endoscopic procedure easier, but it is associated with prolonged hospitalisation, urine extravasation, and postoperative pain and discomfort with a higher analgesic requirement [6]. Since totally tubeless PCNL was first introduced by Wickham et al. [16] in 1984 without external and internal ureteric stents; this approach has gained in popularity and has been found to be associated with shorter hospitalisation, and lower analgesic requirement and nephrostomy tube site complications, but it does not provide access back for a second look in cases of residual stones [6]. The modified supine technique is associated with less postoperative pain and discomfort, lesser hospital stay, less analgesic requirement and provides access back for a second look [17]. In the present study, the safety and effectiveness of the modified supine mini-PCNL was assessed in 50 children.

Our mean operative time was 89.10 min, which was shorter than that reported by Wah et al. [18], with a mean operative time of 109.4 min, mostly because they studied children with larger stones with a median stone burden of 3.44 cm². Whilst, D'Souza et al. [19] reported a shorter mean operative time of 58 min, due to use of holmium yttrium-aluminium-garnet (YAG) laser for stone disintegration in 12 of 20 cases, and they studied children with smaller stones (median stone burden 1.36 cm). On the other hand, Desoky et al. [20] reported a mean operative time of 65.1 min, which was also shorter than our present study as they operated all cases in the supine position, which avoids time loss during the change of patient position to the prone after ureteric catheterisation. The fluoroscopy time is commonly related to operative time, our mean (SD) fluoroscopy time was 7.68 (2.21) min, which is similar to that reported by other studies [18].

Although we performed all cases under fluoroscopic guidance, we acknowledge that ultrasonography guidance is preferred, especially in children, to avoid hazards of radiation exposure. In our present study, we support the fact that mini-PCNL in children is associated with a lesser incidence of perioperative complications. We had one case (2%) of significant bleeding for which 1 unit blood was transfused, one case (2%) had pelvic perforation and extravasation but it was a small perforation and was treated with a JJ stent and conservative measures. These two cases were stone-free and a postoperative nephrostomy tube was inserted in both. We also had two cases (4%) of postoperative fever. Likewise, other studies of mini-PCNL in children, such as Wah et al. [18] reported that one patient (4.8%) developed hydrothorax in which they used a supracostal approach, one patient (4.8%) had a chest infection, and two patients (9.6%) had positive urine cultures but no cases needed blood transfusion. Desoky et al. [20] reported that one patient (4.55%) needed a blood transfusion; postoperative urinoma occurred in two patients (9.1%) and resolved with a JJ stent and conservative measures; postoperative fever occurred in four patients (18.2%). D'Souza and Paul [19] reported that one child (5%) developed postoperative sepsis, one child (5%) developed a postoperative fever, and two children (10%) needed a blood transfusion. In our present study, the mean (SD; range) Hb drop was 0.91 (0.47; 0.50–2.0) g/dL, which was comparable to that reported by Zeng et al. [14] in a retrospective study of mini-PCNL, which found that in children undergoing mini-PCNL the mean (SD; range) Hb drop was 1.46 (0.73; 0.2–3.5) g/dL. Mini-PCNL in children is associated with less bleeding and less blood transfusions than standard PCNL, as reported by other studies of standard PCNL in children, such as Ramchandraiah et al. [10]. In that study of 80 children, standard PCNL was performed in 50 kidneys and mini-PCNL in 40 kidneys, as 10 cases had bilateral stones, the blood transfusion rate was 6% in the standard PCNL group, with no bleeding in the mini-PCNL group. The Dongol et al. [21] study on standard PCNL in 25 children reported a blood transfusion rate of 12%, higher than the transfusion rate in mini-PCNL studies [18–20].

Rare complications, such as visceral injury due to access through the retroperitoneal area can occur and their incidence increases with horseshoe or ectopic kidneys [22]; in our present study, we did not have any unusual complications.

In our experience of the modified supine mini-PCNL in children, externalisation of the ureteric catheter through the flank was done in 48 cases (96%), whilst in two (4%) a nephrostomy tube was inserted at the end of the procedure (one case had a significant bleeding and the other had renal pelvis perforation). The primary SFR was 80% that increased to 100% after successfully treating the residual stones via second-look mini-PCNL after recovering the trackback through the externalised ureteric catheter. This agrees with Zeng et al. [14] who found that the

SFR after a single session of mini-PCNL (initial SFR) was 80.4% that increased to 94.7% after an auxiliary procedure; and the Domenech et al. [7] study of a modified tubeless technique in which they used polypropylene suture externalised at the flank through the track and attached to an internalised ureteric catheter and reported that two patients (15%) required a second-look mini-PCNL after which the SFR increased from 77% to 92%. On the other hand, Wah et al. [18] reported a primary SFR of 83.6%, probably higher than our present study due to the use of a paediatric nephroscope and laser lithotripsy for stone disintegration, which increased to 91.3% after treating the residual fragments; whilst in 8.7% there was a failure to establish a satisfactory PCNL tract. Desoky et al. [20] reported a SFR of 90.9%, which was higher than our present study most probably due to the larger diameter of tract (20 F) and the use of laser lithotripsy for stone disintegration. D'Souza et al. [19] reported a primary SFR of 90%, which was again higher than our present study and most probably due to using a 12-F mini- nephroscope and laser lithotripsy with dusting settings used during lasering.

Our modified supine mini-PCNL technique shortened the patients' postoperative hospital stay and lowered both the pain score and analgesic requirement, as our mean (SD; range) hospital stay was 1.42 (0.53; 1–3) days. This agrees with the Domenech et al. [7] study that reported a median (range) hospital stay of 3 (2–4) days and Chung et al. [6] who found that the modified tubeless group had a mean (SD) of 5.9 (2.7) days, which was shorter than the standard PCNL at 6.8 (2.9) days. On the other hand, our present mean hospital stay was shorter than other studies reporting on conventional mini-PCNL such as Wah et al. [18], who reported a mean (range) hospital stay of 4.78 (2–11) days, D'Souza et al. [19] reported a mean hospital stay of 3 days, and Desoky et al. [20] reported a mean (SD; range) hospital stay of 4.4 (0.9; 3.2–5.9) days.

In our present study, the mean (SD; range) pain score was 2.08 (1.05; 1–5), with a pain score of 5 in the two cases in which a nephrostomy tube was inserted, and the mean (SD; range) postoperative analgesia requirement was 89.8 (8.52; 60–125) mg in which we used diclofenac sodium injection. This agrees with the Chung et al. [6] study, which found that in the modified supine PCNL group the mean (SD) analgesic requirement was 29.8 (59) mg of diclofenac sodium vs standard PCNL group in which the mean (SD) analgesic requirement was 130.5 (177) mg of diclofenac sodium.

Conclusion

We found that the modified supine mini-PCNL in children was safe and effective, and associated with a high SFR, lesser Hb drop and rate of blood transfusion, and lesser incidence of intraoperative and postoperative complications. Also, the modified tubeless technique

gives us the perfect combination of less postoperative pain and analgesic requirement, short hospital stay and at the same time is considered an alternative approach to tubeless surgery that allows a second percutaneous procedure using the same tract.

The most important drawback of mini-PCNL is the lengthy operative time, due to the need for fragmentation into very small stones suitable for ureteroscopic graspers and/or baskets, and the small sheath which may lead to diminished intraoperative field visibility. We think that the technique may be easier when employing stone dusting using a laser lithotripter. We recommend also the use of a suction attachment to the pneumatic lithotripter to decrease the operative time by the extraction of small fragments.

Author's contribution

Sebaey A. Protocol/project development, Data collection or management, Data analysis, Manuscript writing/editing.
Abdelaal A. Protocol/project development, Manuscript writing/editing.
Elshaer A. Protocol/project development, Data collection or management, Data analysis, Manuscript writing/editing.
Alazaby H. Data analysis, Manuscript writing/editing.
Kadeel W. Data analysis, Manuscript writing/editing.
Soliman T. Data analysis, Manuscript writing/editing.
Elbarky E. Data analysis, Manuscript writing/editing.

Disclosure statement

No potential conflict of interest was reported by the authors.

Ethical approval

All procedures performed in this study involving human participants were in accordance with the ethical standards of the institutional research committee and with the 1964 Helsinki declaration and its later amendments.

Informed consent

Informed consent was obtained from all individual participants included in the study.

References

- [1] Smaldone MC, Gayed BA, Ost MC. The evolution of the endourologic management of pediatric stone disease. *Indian J Urol.* 2009;25:302–311.
- [2] Kane CJ, Bolton DM, Stoller ML. Current indications for open stone surgery in an endourology center. *Urology.* 1995;45:218–221.
- [3] Türk C, Petřík A, Sarica K, et al. EAU guidelines on diagnosis and conservative management of urolithiasis. *Eur Urol.* 2016;69:468–474.
- [4] Desai MR, Sharma R, Mishra S, et al. Single-step percutaneous nephrolithotomy (microperc): the initial clinical report. *J Urol.* 2011;186:140–145.
- [5] Ferakis N, Stavropoulos M. Mini percutaneous nephrolithotomy in the treatment of renal and

- upper ureteral stones: lessons learned from a review of the literature. *Urol Ann.* 2015;7:141–148.
- [6] Chung HS, Jung SI, Yu HS, et al. Modified totally tubeless percutaneous nephrolithotomy: is it an effective and safe treatment option for renal and upper ureteral stones? *Wideochir Inne Tech Maloinwazyjne.* 2016;11:240–246.
- [7] Domenech A, Vivaldi B, López JF, et al. Tubeless percutaneous nephrolithotomy without losing the possibility of second-look nephroscopy: the perfect combination [Article in English, Spanish]. *Actas Urol Esp.* 2014;38:334–338.
- [8] Brusky JP, Parekh A, Kaptein J, et al. Need for ancillary procedures among patients undergoing tubeless percutaneous renal surgery for nephrolithiasis. *J Endourol.* 2007;21:692–694.
- [9] Dindo D, Demartines N, Clavien PA. Classification of surgical complications: a new proposal with evaluation in a cohort of a 6336 patients and results of a survey. *Ann Surg.* 2004;240:205–213.
- [10] Ramchandraiah G, Devraj R, Shaik JA, et al. An open label study to evaluate the safety and efficacy of percutaneous nephrolithotomy in children aged 2–14 years. *Int J Contemp Med Res.* 2016;3:3105–3108.
- [11] Yamaguchi A, Skolarikos A, Buchholz NP, et al. Operating times and bleeding complications in percutaneous nephrolithotomy: a comparison of tract dilation methods in 5,537 patients in the clinical research office of the endourological society percutaneous nephrolithotomy global study. *J Endourol.* 2011;25:933–939.
- [12] Mishra S, Sharma R, Garg C, et al. Prospective comparative study of miniperc and standard PNL for treatment of 1 to 2 cm size renal stone. *BJU Int.* 2011;108:896–900.
- [13] Zeng G, Jia J, Zhao Z, et al. Treatment of renal stones in infants comparing extracorporeal shock wave lithotripsy and mini-percutaneous nephrolithotomy. *Urol Res.* 2012;40:599–603.
- [14] Zeng G, Zhao Z, Wan S, et al. Comparison of children versus adults undergoing mini-percutaneous nephrolithotomy: large-scale analysis of a single institution. *PLoS One.* 2013;8:e6685.
- [15] Kirac M, Bozkurt OF, Tunc L, et al. Comparison of retrograde intrarenal surgery and mini-percutaneous nephrolithotomy in management of lower-pole renal stones with a diameter of smaller than 15 mm. *Urolithiasis.* 2013;41:241–246.
- [16] Wickham JE, Miller RA, Kellet MJ, et al. Percutaneous nephrolithotomy: one stage or two? *Br J Urol.* 1984;56:582–585.
- [17] Agrawal MS, Sharma M, Agarwal K. Tubeless percutaneous nephrolithotomy using antegrade tether: a randomized study. *J Endourol.* 2014;28:644–648.
- [18] Wah TM, Kidger L, Kennish S, et al. MINI PCNL in a pediatric population. *Cardiovasc Intervent Radiol.* 2013;36:249–254.
- [19] D'Souza N, Paul S. Mini percutaneous nephrolithotomy for renal calculi in paediatric patients: A review of twenty cases. *Urol Ann.* 2016;8:16–19.
- [20] Desoky EA, ElSayed ER, Eliwa A, et al. Flank-free modified supine percutaneous nephrolithotomy in pediatric age group. *Urology.* 2015;85:1162–1165.
- [21] Singh Dongol UM, Limbu Y. Safety and efficacy of percutaneous nephrolithotomy in children. *J Nepal Health Res Counc.* 2017;15:130–134.
- [22] Bogris S, Papatsoris AG. Status quo of percutaneous nephrolithotomy in children. *Urol Res.* 2010;38:1–5.